

Case Study #8

DISCLAIMER: These pictures are original and are **NOT** to be used anywhere else **WITHOUT my written permission**. Not on any website, publication, etc. To do so would be violating the reasons for putting them up on this site and also stealing.

You may share these and print them out with your students and fellow classmates, but you cannot reproduce them in ANYWAY!

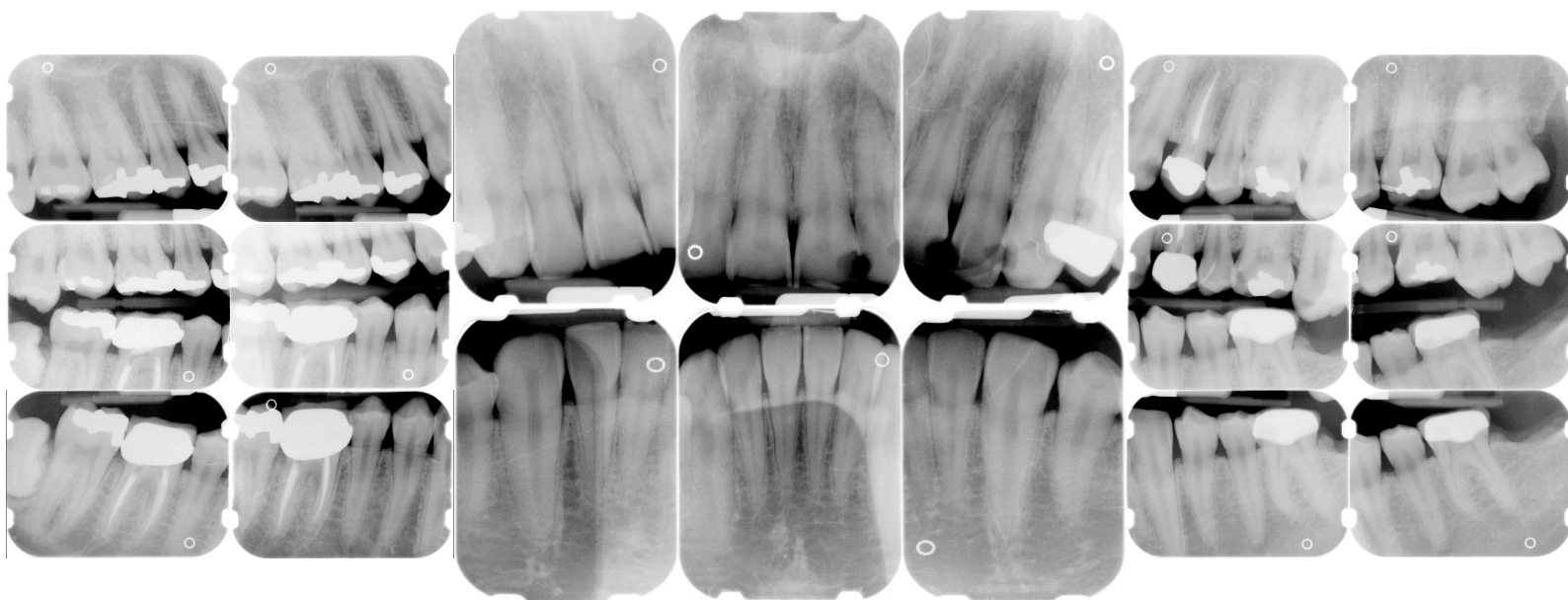
© 2003 Amyrdh.com

Age:
28

Medical History:
No problems, meds
(pt put no meds on med. hx. but upon questioning, pt does take one aspirin a day)
Non-smoker

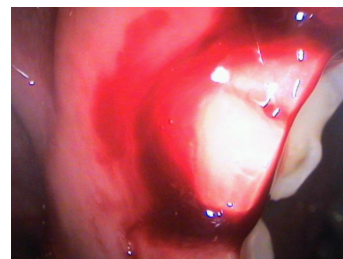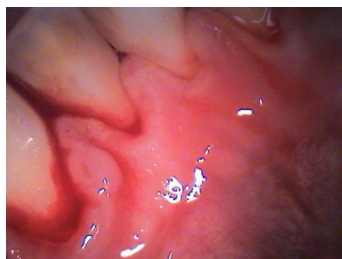
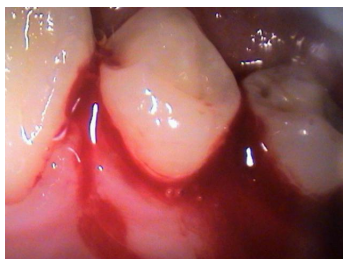
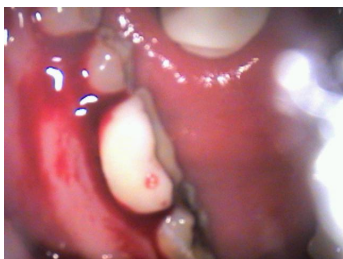Dental History:
Last prophy was in 2001.

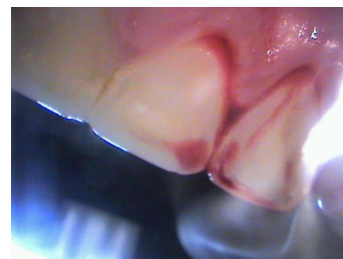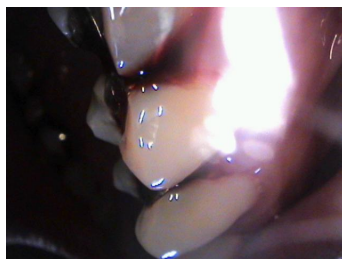
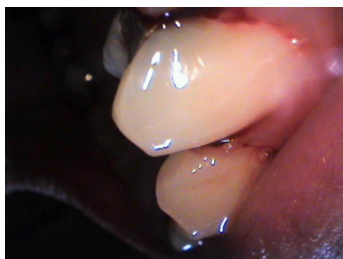
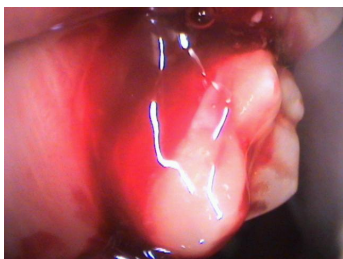
Xrays before treatment:



No Intraoral pics before tx. sorry :(

Intraoral pics after second visit:





Perio Charting:

Date	1	2	3	4	5	6	7	8	9	10	11	12	13	14	15	16
B	4 3 4	4 3 4	4 3 3	3 2 4	4 2 3	3 2 3	3 2 2	2 2 2	2 2 3	3 2 3	3 2 3	3 3 3	3 3 3	3 3 4	4 3 4	4 3 3
L	4 3 4	4 3 4	4 3 4	4 3 5	4 3 3	3 3 4	4 3 3	3 3 3	3 3 4	4 3 4	4 3 4	4 3 4	4 3 4	4 3 4	4 4 4	4 4 4
L	3 3 4	4 3 4	4 3 3	3 3 3	3 3 3	3 2 3	3 2 3	3 2 3	3 2 3	3 2 3	3 2 3	3 2 3	3 3 3	3 3 3	3 3 4	4 3 4
B	4 4 4	4 3 4	4 3 4	4 3 4	4 3 4	3 3 4	4 3 4	4 3 4	4 3 4	4 3 4	4 4 4	4 4 4	4 4 4	4 4 4	4 4 4	4 4 4
L		4 3 4	4 3 4	4 3 4	4 3 4	3 2 3	3 2 3	3 2 3	3 2 3	3 2 3	3 2 3	3 2 3	3 3 3	3 3 3	3 3 4	
B		4 3 4	4 3 3	3 3 3	3 2 3	3 2 3	3 2 3	3 2 3	3 2 3	3 2 3	3 2 3	3 2 4	4 3 4	4 3 4	4 3 4	
		4 4 4	4 4 4	4 3 4	4 3 3	4 3 4	4 3 4	4 3 4	4 3 4	4 3 4	4 3 4	4 3 4	4 3 4	4 3 4	4 3 4	
	32	31	30	29	28	27	26	25	24	23	22	21	20	19	18	17

Summary Data Comparison

Date	Bleeding		Suppuration		Furcation		Mobility	PD > Alert		CAL < 0		CAL 1-3		CAL 4-5		CAL 6+	
	Teeth	Sites	Teeth	Sites	Teeth	Sites	Teeth	Teeth	Sites	Teeth	Sites	Teeth	Sites	Teeth	Sites	Teeth	Sites
15	29	0	0	0	0	0	0	29	174	0	0	29	137	16	37	0	0
28	103	0	0	0	0	0	0	29	174	0	0	24	43	29	131	0	0

Questions:

1. What would you classify this patient's periodontal condition as?
2. Make a treatment plan for this patient.
3. What would you do for patient education?
4. What oral homecare instructions would you recommend for this patient?
5. What referrals would you give for this patient?
6. Would there be any contraindications for this patient during treatment?
7. What recommendations would you give for this patient?
8. What oral homecare aids would you give for this patient?
9. What would be the best instrumentation to disrupt the plaque and bacteria for this patient?
10. On the xrays are there any suspicious areas?
11. Do you think this patient has periodontal disease or active gingivitis?

Questions you might add:

