

## Case Study #6

**DISCLAIMER:** These pictures are original and are **NOT** to be used anywhere else **WITHOUT my written permission**. Not on any website, publication, etc. To do so would be violating the reasons for putting them up on this site and also stealing.

You may share these and print them out with your students and fellow classmates, but you cannot reproduce them in ANYWAY!

© 2003 Amyrdh.com

**Age:**  
35

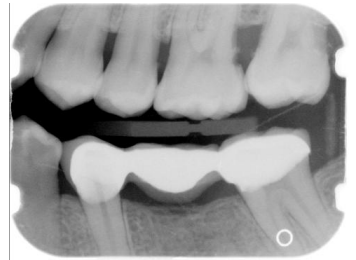
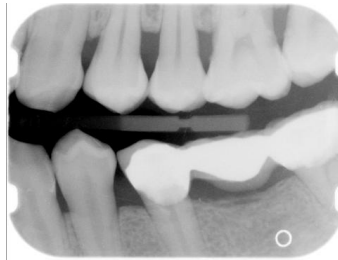
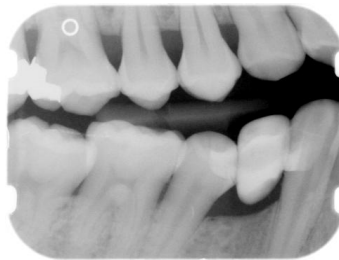
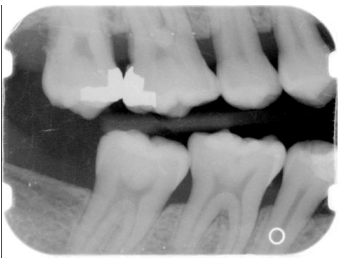**Medical History:**  
No problems, meds  
Non-smoker

**Dental History:**  
SRP was done in 2002 in a different office by the DDS

### Xrays before treatment:

You can click on any pic to see a larger view

Only bwx were taken due to pt having an FMX taken at previous office a year before. We requested xrays. SRP was done in previous office a year before by a DDS.



Intraoral pics before tx:

None on this pt, sorry :(

Perio Charting:

| Date | 1         | 2         | 3         | 4         | 5         | 6         | 7         | 8         | 9         | 10        | 11        | 12        | 13        | 14        | 15        | 16        |
|------|-----------|-----------|-----------|-----------|-----------|-----------|-----------|-----------|-----------|-----------|-----------|-----------|-----------|-----------|-----------|-----------|
| 2    |           | 5 4 5     | 5 5 5     | 5 4 5     | 5 4 5     | 4 3 4     | 4 3 3     | 3 2 3     | 3 2 3     | 3 3 3     | 3 3 4     | 4 3 4     | 4 3 5     | 5 3 8     | 8 3 6     |           |
|      |           | 5 3 5     | 5 3 5     | 5 3 5     | 5 3 4     | 4 3 4     | 4 3 4     | 4 3 4     | 4 3 4     | 4 3 4     | 4 3 4     | 4 3 4     | 5 3 6     | 6 3 8     | 8 3 6     |           |
|      |           | 5 3 5     | 5 3 5     | 5 3 5     |           | 5 3 4     | 4 3 4     | 4 3 4     | 4 3 4     | 4 3 4     | 4 3 4     | 4 3 5     | 5 3 5     |           | 5 3 5     |           |
|      |           | 5 4 4     | 5 4 5     | 4 4 4     |           | 4 3 5     | 5 3 4     | 4 3 5     | 5 3 4     | 4 3 4     | 4 3 5     | 5 3 5     | 5 3 5     |           | 5 3 5     |           |
|      | <u>32</u> | <u>31</u> | <u>30</u> | <u>29</u> | <u>28</u> | <u>27</u> | <u>26</u> | <u>25</u> | <u>24</u> | <u>23</u> | <u>22</u> | <u>21</u> | <u>20</u> | <u>19</u> | <u>18</u> | <u>17</u> |

Summary Data Comparison

| Date | Bleeding |       | Suppuration |       | Furcation |       | Mobility | PD > Alert |       | CAL < 0 |       | CAL 1-3 |       | CAL 4-5 |       | CAL 6+ |       |
|------|----------|-------|-------------|-------|-----------|-------|----------|------------|-------|---------|-------|---------|-------|---------|-------|--------|-------|
|      | Teeth    | Sites | Teeth       | Sites | Teeth     | Sites | Teeth    | Teeth      | Sites | Teeth   | Sites | Teeth   | Sites | Teeth   | Sites | Teeth  | Sites |
|      | 0        | 0     | 0           | 0     | 0         | 0     | 0        | 26         | 156   | 0       | 0     | 26      | 53    | 25      | 95    | 3      | 8     |

Questions:

1. What would you classify this patient's periodontal condition as?
2. Make a treatment plan for this pt.
3. How would you try to overcome this pt's not being able to understand English?
4. What would you do for patient education?
5. Are there any concerns with the medical history?
6. What oral homecare instructions would you use with this patient?
7. What referrals would you give for this patient?
8. Would there be any contraindications for this patient for treatment?
9. What recommendations would you give for this patient?
10. What oral homecare aids would you recommend for this patient?
11. What would be the best instrumentation to use to disrupt the plaque and remove the calculus with this patient?
12. Are there any suspicious areas on the xrays?
13. Do you think this patient has active gingivitis or periodontal disease?

Add your own questions to study from: