

Case Study #4

DISCLAIMER: These pictures are original and are **NOT** to be used anywhere else **WITHOUT my written permission**. Not on any website, publication, etc. To do so would be violating the reasons for putting them up on this site and also stealing.

You may share these and print them out with your students and fellow classmates, but you cannot reproduce them in ANYWAY!

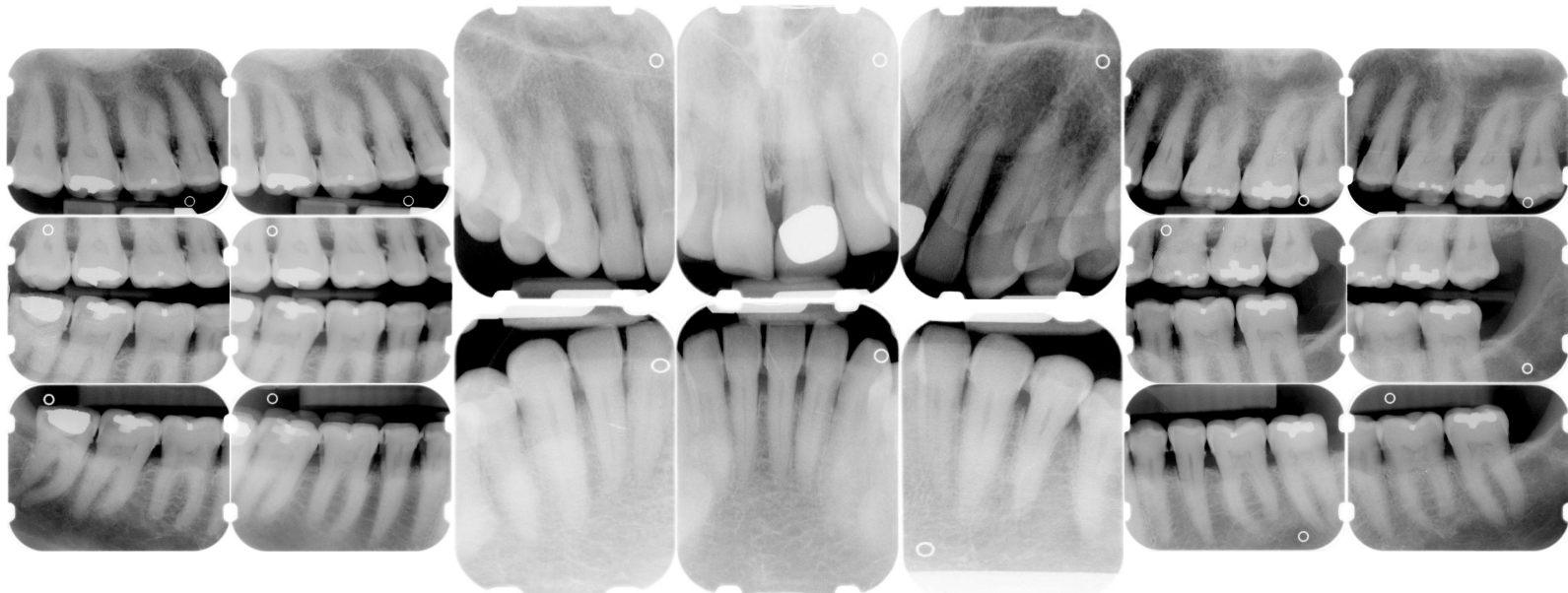
© 2003 Amyrdh.com

Age:
65

Medical History:
HBP
Diabetes
Insulin-dependent

Dental History:
No professional "cleaning" in years
Doesn't like going to the dentist
Pt presents with pain on LR

Xrays before treatment:



www.amyrdh.com

©1998-2003 Amy Nieves

08/31/03 10:24 AM

Questions:

1. What would you classify this patient's periodontal condition as?
2. If this was your patient and they refused treatment and just wanted their teeth "polished" what would you have done?
3. Make a treatment plan for this patient.
4. What would you do for patient education?
5. What oral homecare instructions would you recommend for this patient?
6. What referrals would you give for this patient?
7. Would there be any contraindications for this patient?
8. What recommendations would you give for this patient?
9. What oral homecare aids would you give for this patient?
10. On the xrays are there any suspicious areas?

Questions you might add: