

Case Study #2

DISCLAIMER: These pictures are original and are **NOT** to be used anywhere else **WITHOUT my written permission**. Not on any website, publication, etc. To do so would be violating the reasons for putting them up on this site and also stealing.

You may share these and print them out with your students and fellow classmates, but you cannot reproduce them in ANYWAY!

© 2003 Amyrdh.com

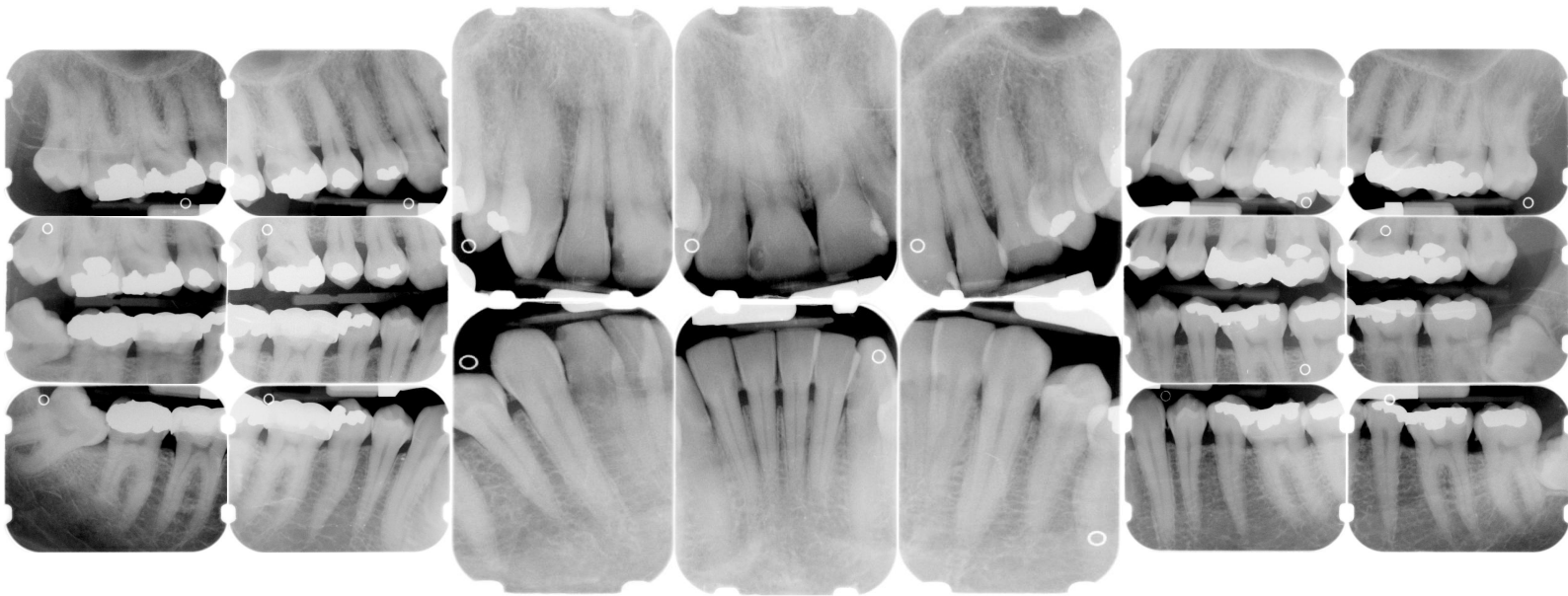
Age:
36

Medical History:
(as filled out by pt -- see tx below)
No problems, meds
Non-smoker

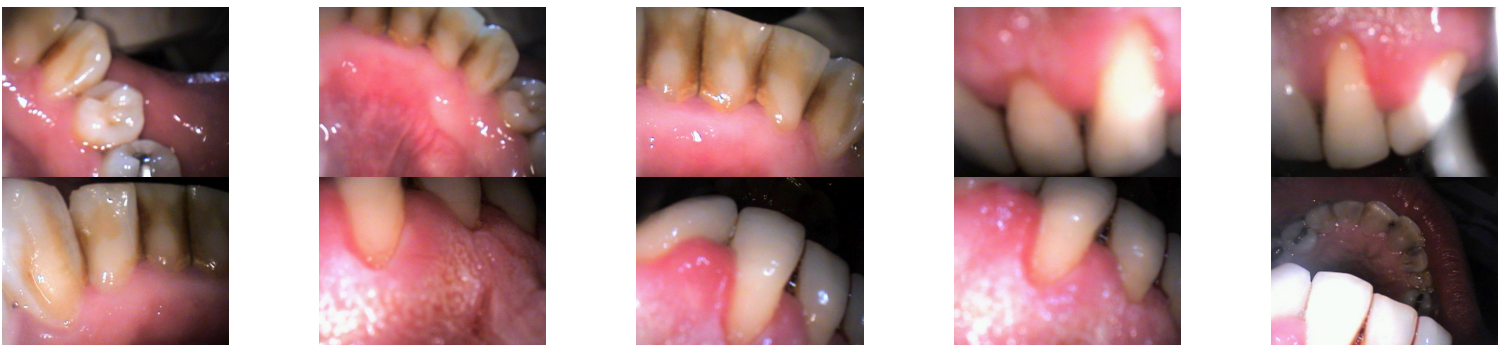Dental History:
Dental phobic
Last "prophy" was in 1984

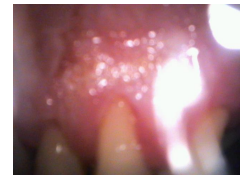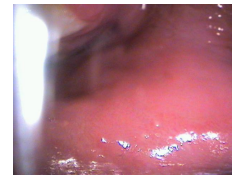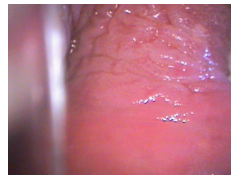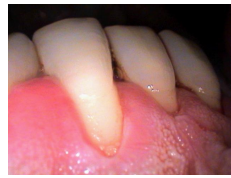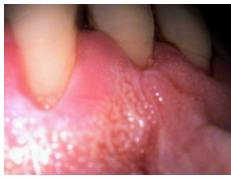Xrays before treatment:

You can click on any pic to see a larger view



Intraoral pics before tx:





Perio Charting:

Date	1	2	3	4	5	6	7	8	9	10	11	12	13	14	15	16	
B	5 4 5	5 4 5	5 4 5	5 4 4	4 4 4	4 4 4	4 4 4	4 4 4	4 4 4	4 4 4	4 4 4	4 4 5	5 4 5	5 4 5	5 4 5	5 4 5	
L	5 5 5	5 5 5	5 4 5	5 4 4	4 4 4	4 3 3	3 3 3	3 3 3	3 3 3	3 3 3	3 3 4	4 4 5	5 4 5	5 4 5	5 4 5	5 5 5	
L	5 5 5	5 5 5	5 4 5	5 4 5	5 4 4	4 3 3	3 3 3	3 3 3	3 3 3	3 3 3	3 3 4	4 4 4	4 4 5	5 5 5	5 5 5		
B	5 5 5	5 5 5	5 4 5	5 4 5	5 4 4	4 4 4	4 4 4	4 4 4	4 4 4	4 4 4	4 4 5	5 4 4	4 4 4	4 4 4	5 4 6	6 4 5	
	<u>32</u>	<u>31</u>	<u>30</u>	<u>29</u>	<u>28</u>	<u>27</u>	<u>26</u>	<u>25</u>	<u>24</u>	<u>23</u>	<u>22</u>	<u>21</u>	<u>20</u>	<u>19</u>	<u>18</u>	<u>17</u>	

Summary Data Comparison

Date	Bleeding		Suppuration		Furcation		Mobility	PD > Alert		CAL < 0		CAL 1-3		CAL 4-5		CAL 6+	
	Teeth	Sites	Teeth	Sites	Teeth	Sites	Teeth	Teeth	Sites	Teeth	Sites	Teeth	Sites	Teeth	Sites	Teeth	Sites
	2	2	0	0	0	0	0	31	154	0	0	12	32	31	152	2	2

Questions:

1. What would you classify this patient's periodontal condition as?
2. This pt did not indicate any history of medical problems or tobacco use on his medical history, based on the intraoral pictures above, what sort of questions might you need to ask further to confirm his medical history?
3. Are you concerned about anything on the intraoral pictures?
4. Make a treatment plan for this patient.
5. What would you do for patient education?
6. What oral homecare instructions would you recommend for this patient?
7. What referrals would you give for this patient?
8. Would there be any contraindications for this patient?
9. What recommendations would you give for this patient?
10. What oral homecare aids would you give for this patient?
11. On the xrays are there any suspicious areas?

Questions you might add: