

## Case Study #25

**DISCLAIMER:** These pictures are original and are **NOT** to be used anywhere else **WITHOUT my written permission**. Not on any website, publication, etc. To do so would be violating the reasons for putting them up on this site and also stealing.

You may share these and print them out with your students and fellow classmates, but you cannot reproduce them in ANYWAY!

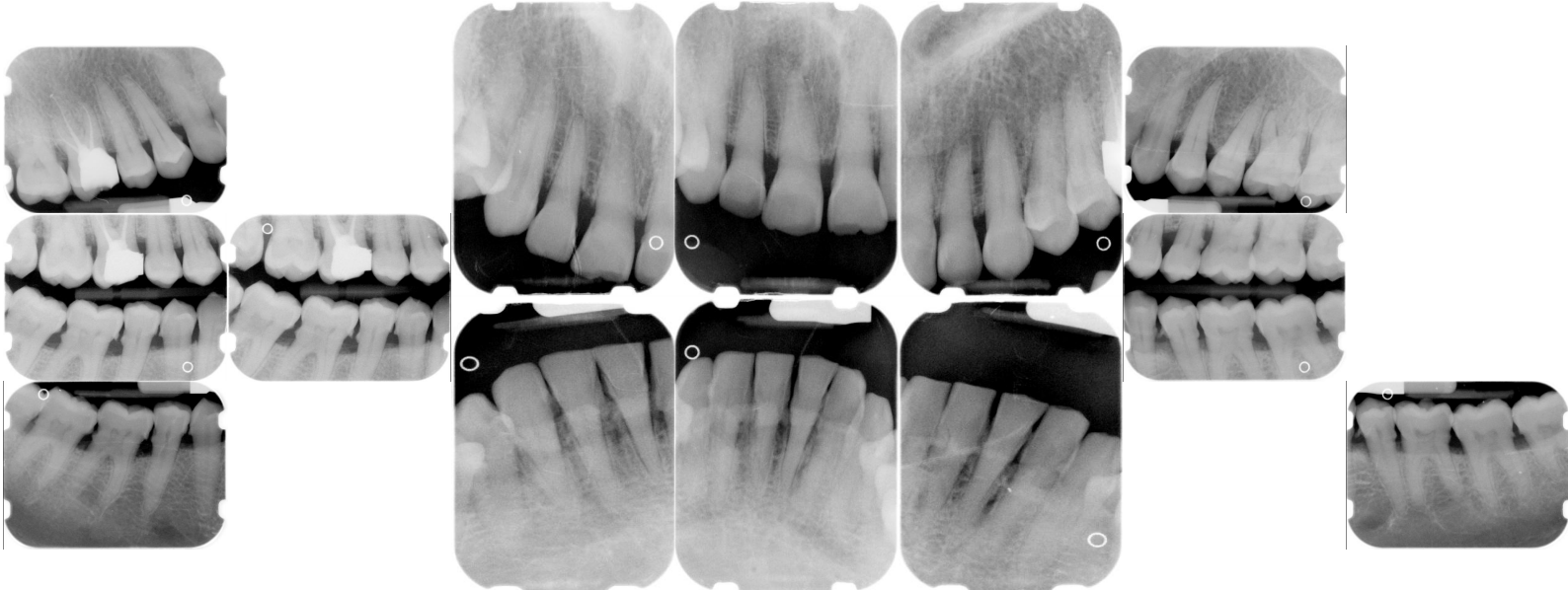
© 2003 Amyrdh.com

Age:  
64 F

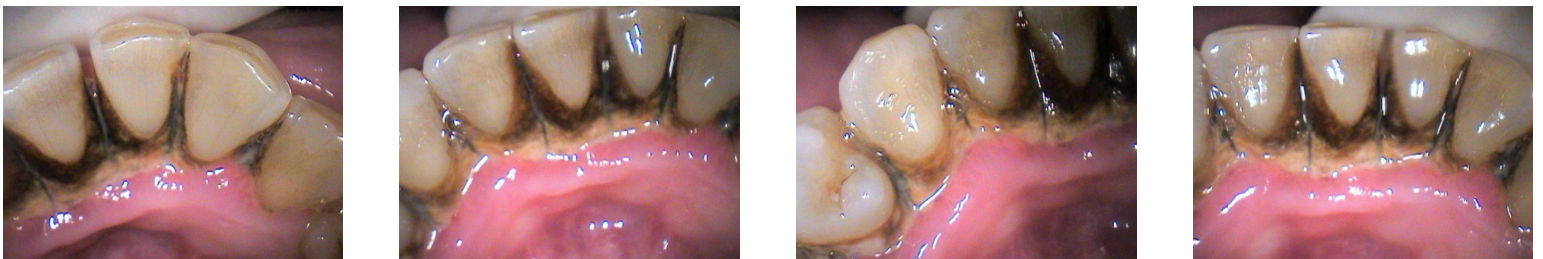
Medical History:  
Smoker

Dental History (Hygiene)  
Pt has never had her teeth  
"professionally" cleaned.  
Apprehensive.

Xrays before treatment:



Intraoral pics before tx:



Perio Charting:

No perio charting done on first visit due to heavy supragingival calculus and pt being so hypersensitive.

Questions:

1. What would you classify this patient's periodontal condition as?
2. Make a treatment plan for this pt.
3. What would you do to try and alleviate this patient's apprehension?
4. What would you do for patient education?
5. Are there any concerns with the medical history?
6. What oral homecare instructions would you use with this patient?
7. What referrals would you give for this patient?
8. Would there be any contraindications for this patient for treatment?
9. What recommendations would you give for this patient?
10. What oral homecare aids would you recommend for this patient?
11. What would be the best instrumentation to use to disrupt the plaque and remove the calculus with this patient?
12. Are there any suspicious areas on the xrays?
13. Do you think this patient has active gingivitis or periodontal disease?

Add your own questions to study from: