

Case Study #24

DISCLAIMER: These pictures are original and are **NOT** to be used anywhere else **WITHOUT my written permission**. Not on any website, publication, etc. To do so would be violating the reasons for putting them up on this site and also stealing.

You may share these and print them out with your students and fellow classmates, but you cannot reproduce them in ANYWAY!

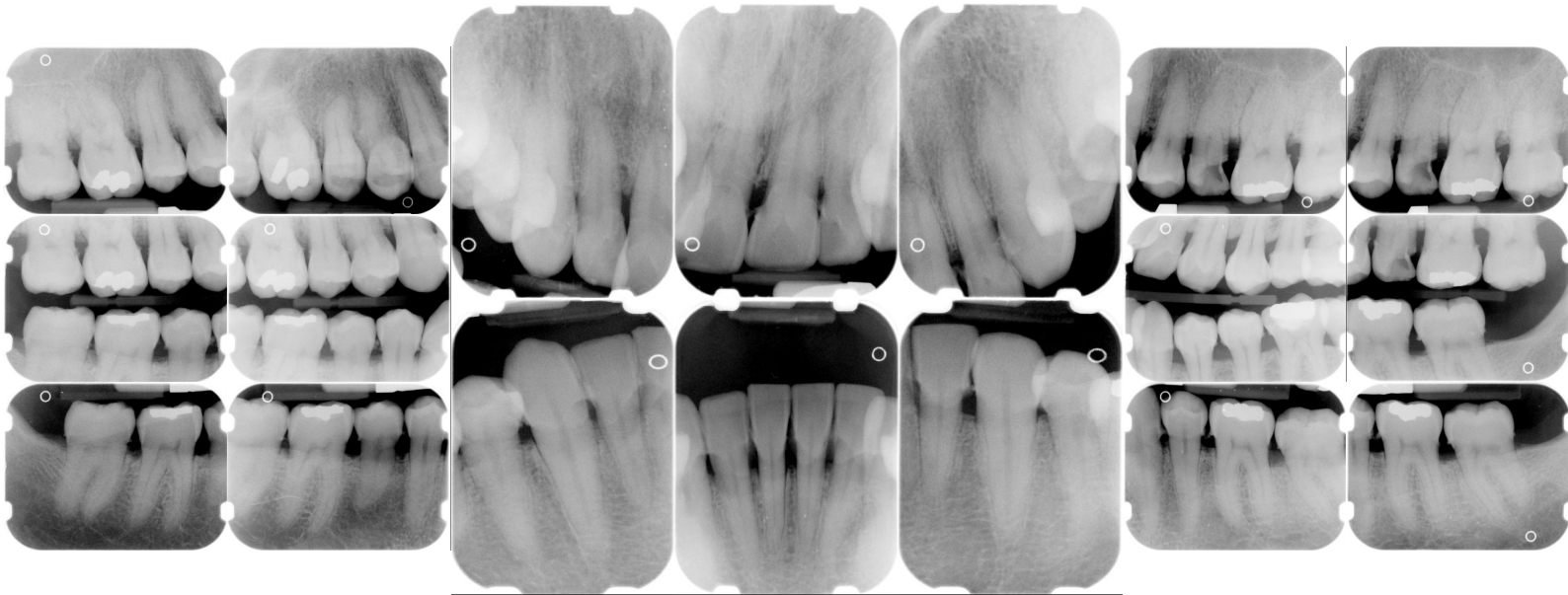
© 2003 Amyrdh.com

Age:
35 M

Medical History:
HBP
Non-smoker

Dental History:
It has been 17 years since last dental visit.

Xrays before treatment:



No Intraoral pics before tx. sorry :(

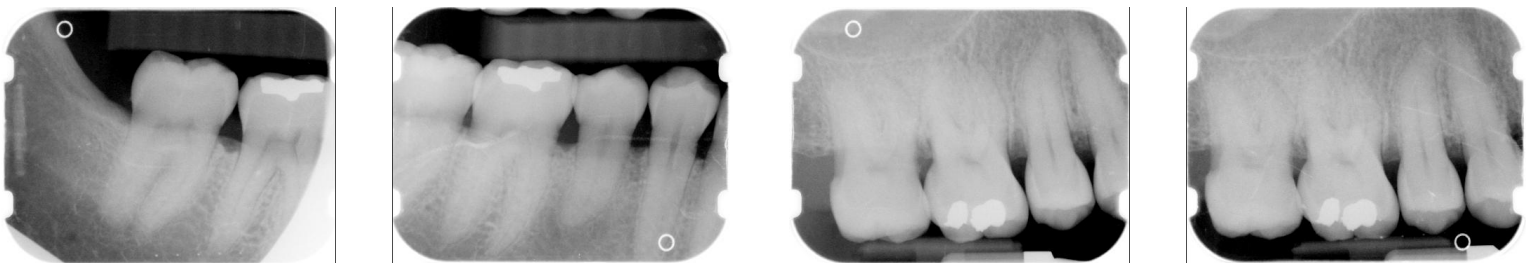
Perio Charting:

| Date | 1 | 2 | 3 | 4 | 5 | 6 | 7 | 8 | 9 | 10 | 11 | 12 | 13 | 14 | 15 | 16 | |
|------|---|-------|-------|-------|-------|-------|-------|-------|-------|-------|-------|-------|-------|-------|-------|-------|----|
| B | | 5 4 5 | 5 4 5 | 5 4 4 | 4 4 5 | 5 4 4 | 4 4 5 | 5 4 4 | 4 4 5 | 5 4 4 | 4 4 4 | 4 4 5 | 5 4 5 | 5 4 5 | 5 4 5 | 5 4 5 | |
| L | | 5 4 6 | 6 4 5 | 5 4 5 | 5 4 4 | 4 3 4 | 4 3 4 | 4 3 4 | 4 3 4 | 4 3 4 | 4 3 4 | 4 4 5 | 5 4 5 | 5 5 5 | 5 5 5 | | |
| L | | 5 5 5 | 5 4 5 | 5 4 5 | 5 4 5 | 4 3 4 | 4 3 4 | 4 3 4 | 4 3 4 | 4 3 4 | 4 3 4 | 4 4 5 | 5 4 5 | 5 4 5 | 5 4 5 | | |
| B | | 5 4 5 | 5 4 5 | 5 4 4 | 4 4 4 | 4 3 4 | 4 3 4 | 4 3 4 | 4 3 4 | 4 3 4 | 4 3 5 | | 5 4 5 | 5 4 5 | 5 4 5 | | |
| | | 6 5 5 | 5 4 4 | 4 4 4 | 4 4 4 | 4 4 4 | 4 4 4 | 4 4 4 | 4 4 4 | 4 4 4 | 4 4 4 | | 4 4 5 | 5 4 5 | 5 4 5 | | |
| | | 32 | 31 | 30 | 29 | 28 | 27 | 26 | 25 | 24 | 23 | 22 | 21 | 20 | 19 | 18 | 17 |

Summary Data Comparison

| Date | Bleeding | | Suppuration | | Furcation | | Mobility | PD > Alert | | CAL < 0 | | CAL 1-3 | | CAL 4-5 | | CAL 6+ | |
|------|----------|-------|-------------|-------|-----------|-------|----------|------------|-------|---------|-------|---------|-------|---------|-------|--------|-------|
| | Teeth | Sites | Teeth | Sites | Teeth | Sites | Teeth | Teeth | Sites | Teeth | Sites | Teeth | Sites | Teeth | Sites | Teeth | Sites |
| 0 | 0 | 0 | 0 | 0 | 0 | 0 | 0 | 27 | 144 | 0 | 0 | 12 | 18 | 27 | 142 | 2 | 2 |
| 17 | 101 | 0 | 0 | 0 | 0 | 0 | 0 | 27 | 146 | 0 | 0 | 6 | 16 | 27 | 124 | 12 | 22 |

Xrays after tx:
Still worked after these pics to remove residual radiographic calculus



Questions:

1. What would you classify this patient's periodontal condition as?
2. Make a treatment plan for this patient.
3. What would you do for patient education?
4. What oral homecare instructions would you recommend for this patient?
5. What referrals would you give for this patient?
6. Would there be any contraindications for this patient during treatment?
7. What recommendations would you give for this patient?
8. What oral homecare aids would you give for this patient?
9. What would be the best instrumentation to disrupt the plaque and bacteria for this patient?
10. What would be the best instrumentation to remove the heavy subgingival calculus?
11. On the xrays are there any suspicious areas?
12. Do you think this patient has periodontal disease or active gingivitis?

Questions you might add: