

Case Study #18

DISCLAIMER: These pictures are original and are **NOT** to be used anywhere else **WITHOUT my written permission**. Not on any website, publication, etc. To do so would be violating the reasons for putting them up on this site and also stealing.

You may share these and print them out with your students and fellow classmates, but you cannot reproduce them in ANYWAY!

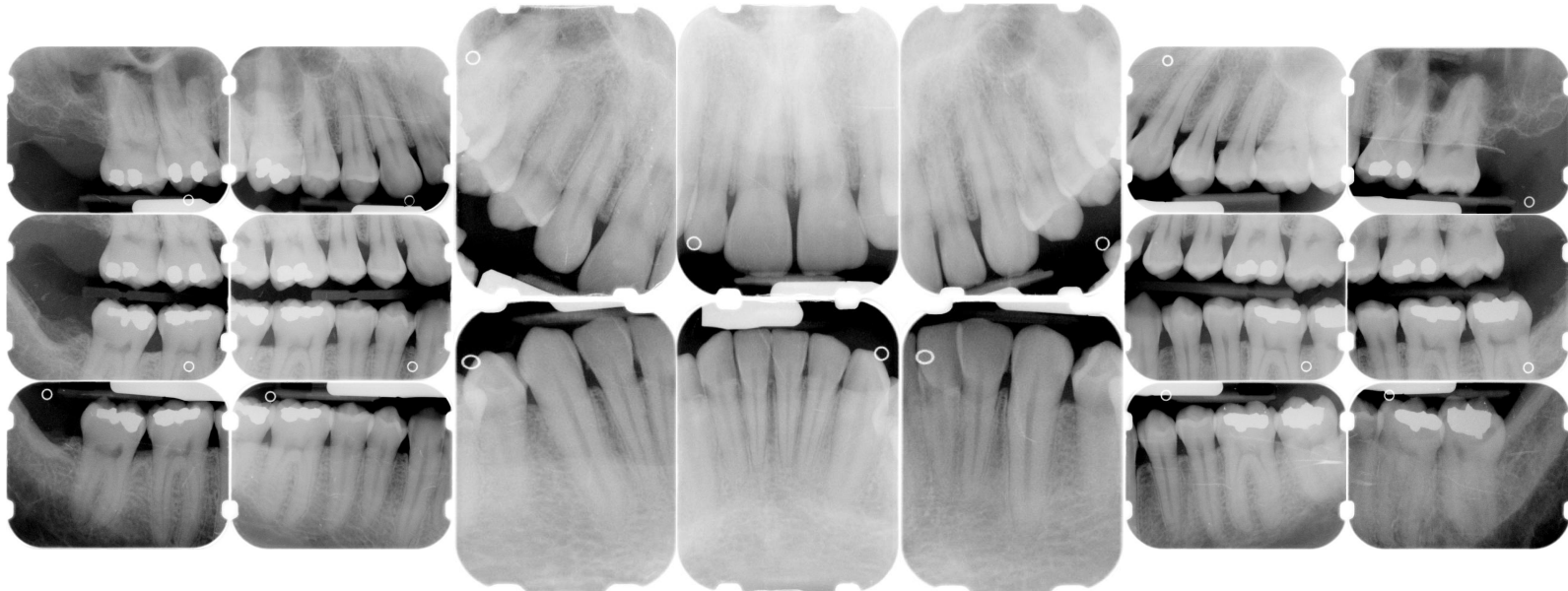
© 2003 Amyrdh.com

Age:
37 M

Medical History:
No problems, meds
Smoker

Dental History:
It has been 11-12 years since last dental visit.

Xrays before treatment:



Perio Charting:

Date	1	2	3	4	5	6	7	8	9	10	11	12	13	14	15	16
		5 4 5	5 4 5	5 4 5	5 4 5	4 3 4	4 2 3	3 2 2	2 2 2		3 2 3	3 3 4	4 3 5	5 4 5	5 4 5	
		5 4 5	5 4 5	5 4 5	5 4 4	4 3 3	3 3 4	4 3 4	4 3 3		4 3 4	4 4 5	5 4 5	5 4 5	5 5 6	
		5 4 5	5 4 5	5 4 5	5 4 4	3 3 3	3 3 3	3 3 3	3 3 3	3 3 3	3 3 4	4 4 5	5 4 5	5 4 5	5 4 5	
		5 4 5	5 4 5	5 4 5	5 4 5	4 3 4	4 3 4	4 3 4	4 3 4	4 3 4	4 3 4	4 4 4	4 4 5	5 4 5	5 4 5	
	<u>32</u>	<u>31</u>	<u>30</u>	<u>29</u>	<u>28</u>	<u>27</u>	<u>26</u>	<u>25</u>	<u>24</u>	<u>23</u>	<u>22</u>	<u>21</u>	<u>20</u>	<u>19</u>	<u>18</u>	<u>17</u>

Summary Data Comparison

Date	Bleeding		Suppuration		Furcation		Mobility	PD > Alert		CAL < 0		CAL 1-3		CAL 4-5		CAL 6+	
	Teeth	Sites	Teeth	Sites	Teeth	Sites	Teeth	Teeth	Sites	Teeth	Sites	Teeth	Sites	Teeth	Sites	Teeth	Sites
	16	58	0	0	0	0	0	27	116	0	0	13	46	27	115	1	1

Questions:

1. What would you classify this patient's periodontal condition as?
2. Make a treatment plan for this pt.
3. What would you do for patient education?
4. Are there any concerns with the medical history?
5. What oral homecare instructions would you use with this patient?
6. What referrals would you give for this patient?
7. Would there be any contraindications for this patient for treatment?
8. What recommendations would you give for this patient?
9. What oral homecare aids would you recommend for this patient?
10. What would be the best instrumentation to use to disrupt the plaque and remove the calculus with this patient?
11. Are there any suspicious areas on the xrays?
12. Do you think this patient has active gingivitis or periodontal disease?
13. If this pt. kept coming back and not complying with homecare, what would you do to change your approach to homecare?

Add your own questions to study from: