

Case Study #14

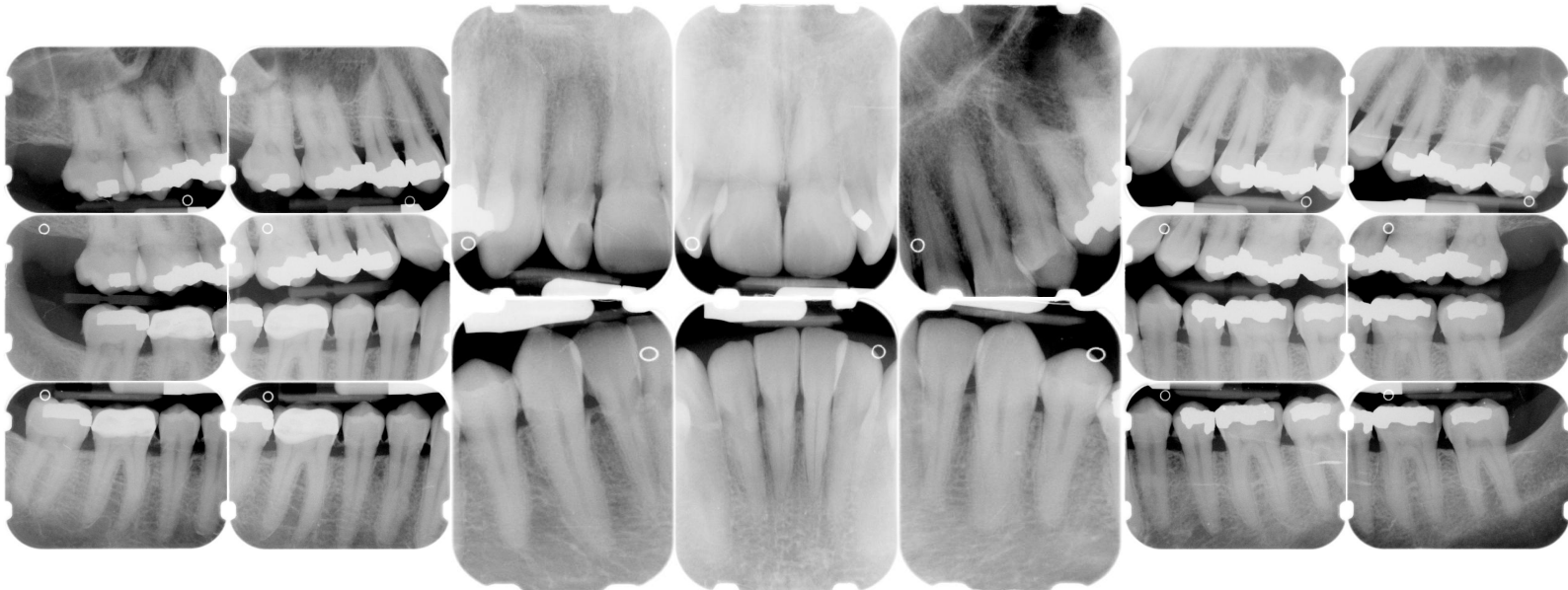
DISCLAIMER: These pictures are original and are **NOT** to be used anywhere else **WITHOUT my written permission**. Not on any website, publication, etc. To do so would be violating the reasons for putting them up on this site and also stealing.

You may share these and print them out with your students and fellow classmates, but you cannot reproduce them in **ANYWAY!**

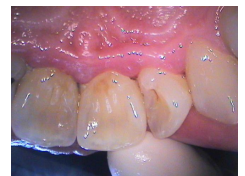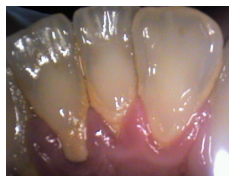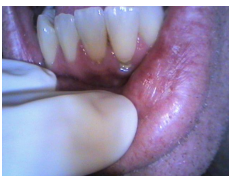© 2003 Amyrdh.com

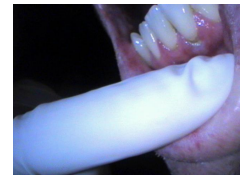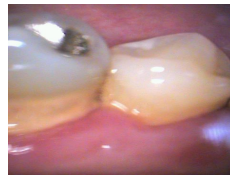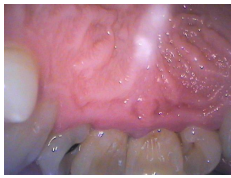<p>Age: 45 M</p>	<p>Medical History: Pt had a heart attack in 2002 HBP MD was called before any tx No premed needed MD stated no EPI to be used Non-smoker Meds Lipitor, Altace, Cartia XT</p>	<p>Dental History (Hygiene) Pt had not had his teeth "cleaned" in about 18 years. Doesn't like visiting the dentist. Sensitive teeth. amalgam tattoo on left buccal mucosa adjacent to 2nd molar. Referral to oral surgeon to get that area checked out.</p>
-----------------------------	--	---

Xrays before treatment:



Intraoral pics before tx:





Perio Charting:

Date	1	2	3	4	5	6	7	8	9	10	11	12	13	14	15	16	
B		5 4 5	5 4 5	5 4 5	5 4 4	4 3 4	4 3 4	4 3 4	4 4 4	4 4 4	4 4 4	4 4 4	4 4 5	5 4 6	6 4 5		
L		5 4 5	5 4 5	5 4 5	5 4 5	4 4 5	5 4 5	5 4 4	4 4 4	4 4 4	4 4 4	5 4 5	5 4 5	5 4 6	6 4 5		
L		5 4 5	5 4 5	5 4 5	5 4 5	4 4 4	4 4 4	4 4 4	4 4 4	4 4 4	4 4 4	4 4 5	5 4 5	5 4 5	5 4 5		
B		5 4 5	5 4 5	5 4 5	5 4 4	4 4 5	4 4 5	4 4 4	4 4 4	4 4 3	3 4 3	4 4 5	5 4 5	5 4 5	5 4 5		
		32	31	30	29	28	27	26	25	24	23	22	21	20	19	18	17

Summary Data Comparison

Date	Bleeding		Suppuration		Furcation		Mobility	PD > Alert		CAL < 0		CAL 1-3		CAL 4-5		CAL 6+	
	Teeth	Sites	Teeth	Sites	Teeth	Sites	Teeth	Teeth	Sites	Teeth	Sites	Teeth	Sites	Teeth	Sites	Teeth	Sites
	27	107	0	0	0	0	0	28	162	0	0	5	6	28	155	5	7

www.amyrdh.com
 ©1998-2003 Amy Nieves
 08/31/03 10:28 AM

Questions:

1. What would you classify this patient's periodontal condition as?
2. Considering the patient's medical history, what would be the FIRST thing to do before even seeing this patient?
3. Make a treatment plan for this patient.
4. What would you do for patient education?
5. What oral homecare instructions would you recommend for this patient?
6. What referrals would you give for this patient?
7. Would there be any contraindications for this patient during treatment?
8. What recommendations would you give for this patient?
9. What oral homecare aids would you give for this patient?
10. On the xrays are there any suspicious areas?

Questions you might add: